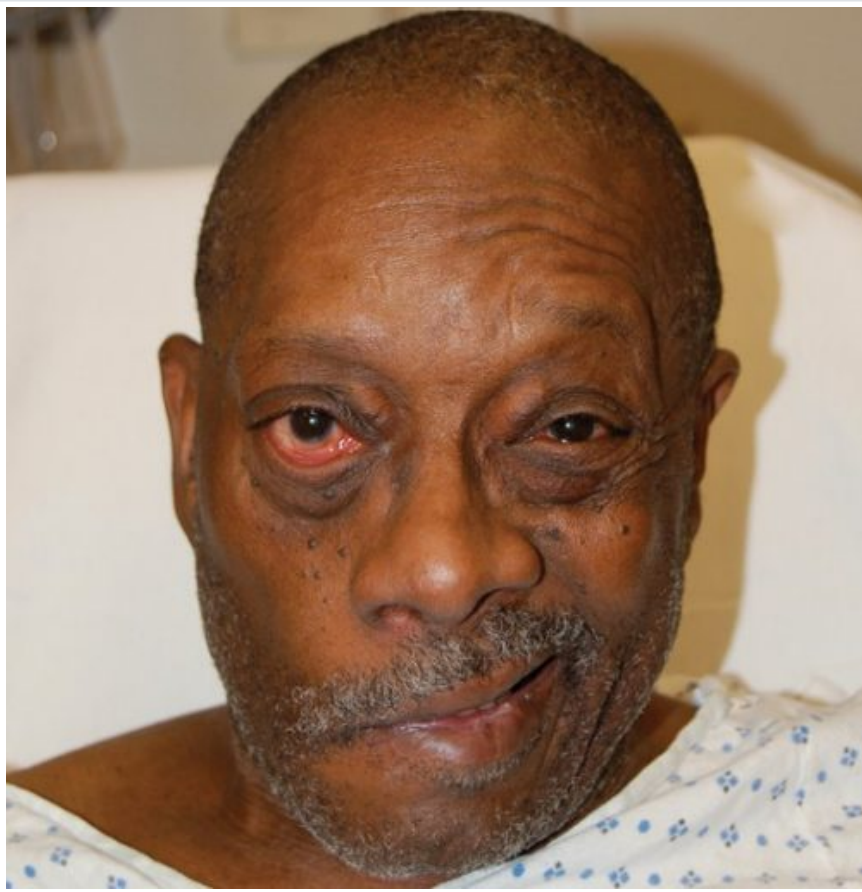

# Differentiating Facial Weakness Caused by Bell's Palsy vs. Acute Stroke

Can you tell the difference?

Wed, May 7, 2014 | By [Caitlin Loomis, MD](#) [Caitlin Loomis, MD], [Michael T. Mullen, MD](#) [Michael T. Mullen, MD]



*Is it Bell's palsy or an acute stroke? Photo Edward T. Dickinson*

## Learning Objectives

- Learn the basic anatomy of facial muscle control.
- Recognize the common clinical presentation of Bell's palsy and ischemic stroke.
- Understand how to rapidly assess a patient with acute facial weakness to differentiate between Bell's palsy and ischemic stroke.

You're responding to a 54-year-old woman with facial weakness. The patient states she looked in the mirror this morning and noticed her face appeared "twisted." She didn't notice any facial asymmetry before going to bed the night before. She complains of no pain or numbness.

Your assessment shows the right side of her mouth isn't able to smile and she has difficulty closing her right eye. You perform a neurologic exam; strength and sensation are normal throughout, with no weakness in the arms or legs and no other neurologic findings. She's able to communicate and answers all questions appropriately. Is this a stroke?

## Facial Weakness

The two most common causes of acute facial paralysis are Bell's palsy and ischemic stroke.<sup>1</sup> EMS providers are often faced with the challenge of differentiating between these two diagnoses. Because acute stroke is a time-critical illness, the distinction between stroke and Bell's palsy must be made quickly to avoid unnecessary delays in treatment.

### Anatomy of Facial Muscle Control

Two facial nerves, the right and the left, control all of the muscles in the face. The right facial nerve controls all of the muscles on the right side and the left facial nerve controls all of the muscles on the left side of the face. The facial nerves emerge from the middle of the brainstem (the pons) and carry motor fibers to the muscles of facial expression. These fibers come from the motor cortex of both cerebral hemispheres. From their origin in the motor strip of the cortex, they can be split into additional fibers that supply muscles in the upper face, including those controlling eye closure and forehead movement, and fibers that supply muscles in the lower face, including the mouth.

The fibers that control the lower face travel from the cortex down to the brainstem. In the brainstem, these fibers cross over to the opposite, or contralateral, facial nerve.

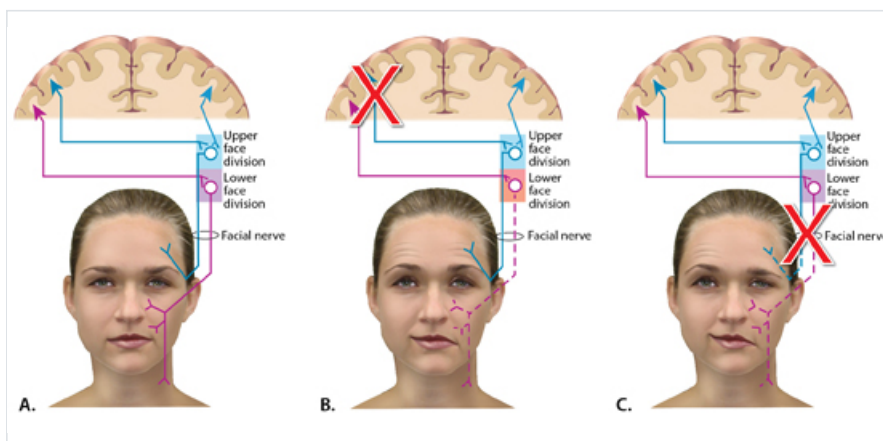
The fibers that control the upper face take a slightly different path. After travelling down to the brainstem, half of the fibers cross over to the contralateral facial nerve, and half remain on the same side and contribute to the ipsilateral facial nerve.

Therefore, the eyes and forehead receive innervation from both hemispheres, while the lower face only receives innervation from the contralateral hemisphere.<sup>2</sup>

Why does this matter? The strictly contralateral innervation of the lower half of the face and dual innervation of the upper half of the face is critical when assessing facial weakness. Lesions that damage the motor cortex, such as acute ischemic strokes, will result in contralateral facial weakness of the lower face only, with preservation of the muscles of the upper face on both sides, due to the dual innervation of the upper face. Patients will have a weak smile, but will be able to close their eye tightly and wrinkle their forehead symmetrically. This pattern is often referred to as "central facial weakness," because it's caused by injury to the cerebral cortex, which is a part of the central nervous system.

Lesions that damage the facial nerve in the brainstem, or after it exits the brainstem, result in ipsilateral facial weakness involving both the upper and lower face. It doesn't matter where the innervation is coming from; if the nerve is damaged, all the muscles on that side of the face are weak. These lesions are referred to as "peripheral lesions" because they affect the facial nerve as it exits the brainstem. Patients will be unable to wrinkle their forehead, tightly close their eye, or smile on the affected side. This distinction can aid in localizing the lesion to the appropriate place in the nervous system, thereby narrowing the differential diagnosis.

**Figure 1: Pathway of the facial nerve**



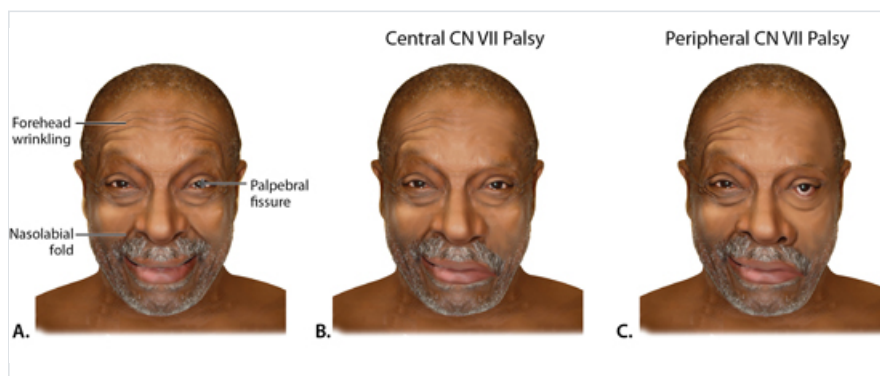
**A) The innervation to the muscles of the upper face originates on both sides of the brain, whereas the innervation to the muscles of the lower face comes from the opposite side of the brain only. B) When the cortex is injured, there's weakness in the contralateral lower face only. C) When the facial nerve is injured, there's weakness in the ipsilateral upper and lower face. Illustration Brook Wainwright Designs**

## Bell's Palsy

Bell's palsy is an acute peripheral facial nerve palsy of unknown etiology, causing rapid onset of facial weakness. It's the most common cause of facial nerve injury.<sup>3</sup> Deficits accumulate over hours to days, and reach maximum severity within three weeks. The symptoms may also develop at night while the patient is sleeping, making them seem more acute. Facial weakness typically recovers—partially or fully—within six months. Although Bell's palsy can affect patients of any age, the median age of onset is 40 years, and it's more common in patients in their third to fifth decade.<sup>1, 3,4</sup>

As Bell's palsy affects the facial nerve, it causes facial weakness in a peripheral pattern—that is, weakness involving the mouth, eye and forehead. Specific clinical features include: weakness raising the eyebrow and furrowing the brow; difficulty or inability to close the eye; weakness in grimacing and smiling; and flattening of the nasolabial fold. Although the exact cause of Bell's palsy is often unknown, infectious causes are thought to contribute in the majority of cases. It's widely believed that the most common cause is reactivation of herpes simplex virus-1.<sup>1</sup> Bell's palsy is treated with a 10-day course of steroids. In some cases antiviral therapy may also be prescribed. While some patients are left with permanent facial paralysis, the majority of patients with Bell's Palsy experience a complete, or near complete, recovery.<sup>3</sup>

**Figure 2: Patterns of facial weakness**



**A) Normal anatomic landmarks during smiling and raising the eyebrows. B) On the left, the nasolabial fold is flat and the mouth is turned down but the forehead wrinkles are intact and the palpebral fissures are symmetric. C) On the left, the nasolabial fold is flat, the mouth is turned down, the forehead is not wrinkled and the palpebral fissure is widened. Illustration Brook Wainwright Designs**

## Acute Stroke

Acute ischemic stroke is due to an occlusion of an artery supplying the brain. Deficits are abrupt in onset and typically reach maximum severity within seconds to minutes. In stroke, the pattern of symptoms is determined by the arterial supply of the affected blood vessel and should therefore correspond to a known vascular distribution in the brain or brainstem.

Facial weakness can be caused by strokes in many different locations in the brain and brainstem. Strokes involving the brain typically cause central facial weakness that involves the mouth and spares the eye and forehead. Strokes involving the brainstem can sometimes cause weakness of the mouth, eye and forehead—mimicking a peripheral lesion. In these cases however, there will be other focal neurologic deficits. A review of systems and neurologic examination can help to identify signs and symptoms of stroke.

**Table 1: Typical presentation of Bell's palsy and acute stroke**

	Bell's palsy	Acute stroke
Age	20s-50s	> 60
Time course	Hours to a few days	Seconds to minutes
Upper face	Always affected	+/- affected
Lower face	Always affected	Always affected
Associated symptoms	Typically none (Rare facial numbness)	Weakness, numbness, speech difficulty, slurred speech, double vision, facial numbness, difficulty swallowing, vertigo, ataxia

## Bell's Palsy vs. Stroke

Differentiating a Bell's palsy from an acute ischemic stroke can be achieved by following these steps:

**1. Talk to the patient.** Ask the patient when they first noticed the weakness and how quickly it developed. Although both Bell's palsy and acute stroke cause "acute" facial weakness, ischemic stroke is much more acute in onset, reaching maximum severity within seconds to minutes. Bell's palsy reaches maximum severity within hours to a few days. Patients often don't know the exact time of onset, but family members, co-workers, or other witnesses may have more information. It's crucial to determine the time they were last seen normal when assessing onset, rather than the time they first noticed the deficit.

**2. Perform a brief neurologic exam.** You want to determine if the facial weakness is caused by a peripheral or central lesion.

- **Mouth:** First, inspect the patient's mouth. Look at the nasolabial fold—the wrinkle between the corner of their nose and the corner of their mouth. Facial weakness or drooping can obscure this wrinkle, as the face is pulled down by gravity. Next, have the patient smile. If the facial palsy is severe, they'll be unable to lift the side of their mouth. If the patient is able to smile symmetrically but has flattening of the nasolabial fold, this is still a sign of mild facial weakness. Mouth weakness will be present in both central and peripheral facial palsies.
- **Eyes:** First, inspect the eyes at rest. Look at the palpebral fissure—the space between the eyelids—to determine if one eye is opened more widely than the other. This may be a subtle sign of eye closure weakness. Next, ask the patient to close their eyes tightly. Normally, patients should be able to squeeze their eyes so tightly that the eyelashes are no longer visible. Asymmetry in eyelid closure is a sign of peripheral facial nerve palsy.
- **Forehead:** Have the patient wrinkle their forehead, as if they're surprised. In a central lesion, the forehead should lift symmetrically, due to bilateral cortical innervation of the frontalis muscle. However, in a peripheral lesion, the patient will be unable to wrinkle their forehead on one side, or have fewer wrinkles on that side. Asymmetry in forehead wrinkles is a sign of peripheral facial nerve palsy.

Once you've performed this quick exam, you should be able to determine if the lesion is peripheral or central. If central, it can't be Bell's palsy and the most likely etiology is stroke. If it's peripheral in appearance it's likely Bell's palsy, but you have to do a little more work to be sure. Although the majority of acute strokes are due to damage to the cerebral hemispheres, therefore causing a central facial palsy, it's possible to have a stroke affecting only the brainstem. Brainstem strokes can affect the facial nerve as it travels through the brainstem, causing facial weakness in the same pattern as that of Bell's palsy. So how can you tell the difference?


**3. Look for associated signs/symptoms.** A key to differentiating acute stroke from Bell's palsy in the presence of peripheral facial weakness is to determine if the weakness could be due to a brainstem stroke. Due to the vascular supply of the brainstem, brainstem strokes typically affect multiple cranial nerves in addition to either motor or sensory tracts traveling to the spinal cord.<sup>2</sup> Bell's palsy, on the other hand, typically affects only the facial nerve, causing only peripheral facial weakness. Key signs to look for include the following:

- **Weakness or numbness in the arm or leg:** Weakness or numbness can occur either on the same side as the facial palsy, or on the opposite side, due to the crossing sensory and motor fibers in the brainstem. Have the patient lift their arms and legs to assess for any weakness.

- **Slurred speech (dysarthria):** Slurred speech secondary to brainstem ischemia is often due to a cranial neuropathy. In addition to standard conversation, you can have the patient say a few words like “baseball player,” “fifty-fifty” and “tip-top.”
- **Double vision (diplopia):** Double vision is often caused by misalignment of the eyes due to a cranial neuropathy affecting the extraocular muscles. Ensure that the patient is able to move his or her eyes in all directions (up, down, right, left) to rule out any abnormalities in the extraocular muscles, and ask the patient if they’re seeing double.
- **Facial numbness:** Rarely, Bell’s palsy can affect the trigeminal nerve, which supplies sensation to the face. It’s unclear whether facial numbness is due to an additional cranial neuropathy (trigeminal neuropathy) or altered sensation in the setting of a drooping face. Other cranial neuropathies are infrequent and should raise a high index of suspicion for stroke or other, more serious, causes of facial weakness.<sup>5</sup>
- **Difficulty swallowing (dysphagia):** Dysphagia secondary to brainstem ischemia is often due to a cranial neuropathy. Ask the patient if they’re having trouble swallowing, or if they’ve noticed any coughing while swallowing.
- **Incoordination (ataxia):** Ataxia can be caused by damage to the brainstem or cerebellum. It’s common to have both cerebellar and brainstem ischemia due to the same stroke. Ask the patient if they’ve felt off-balance while walking. Have the patient walk and perform finger-nose-finger testing to assess for any incoordination of the extremities.
- **Vertigo:** Vertigo, or the sensation of perceived movement in the absence of actual movement, is another common feature of brainstem or cerebellar strokes. Patients may state the sensation of nausea, room spinning, or feeling as if they’re on a boat.

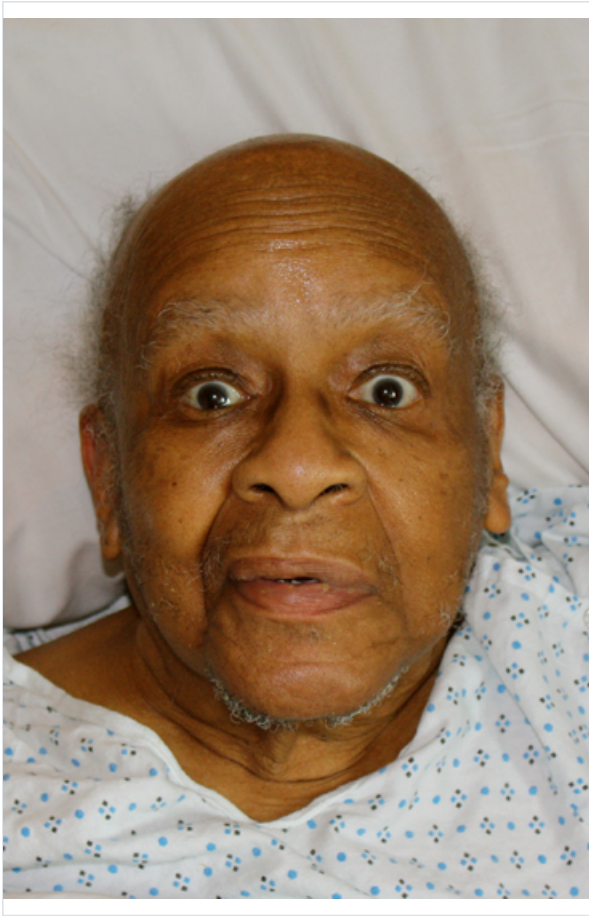If the patient has any of these features present on exam, it’s most likely a stroke, as the territory involved includes more than just the facial nerve. If the patient has a peripheral pattern of weakness and nothing else, it’s most likely Bell’s palsy.

**Figure 3: Patient images**

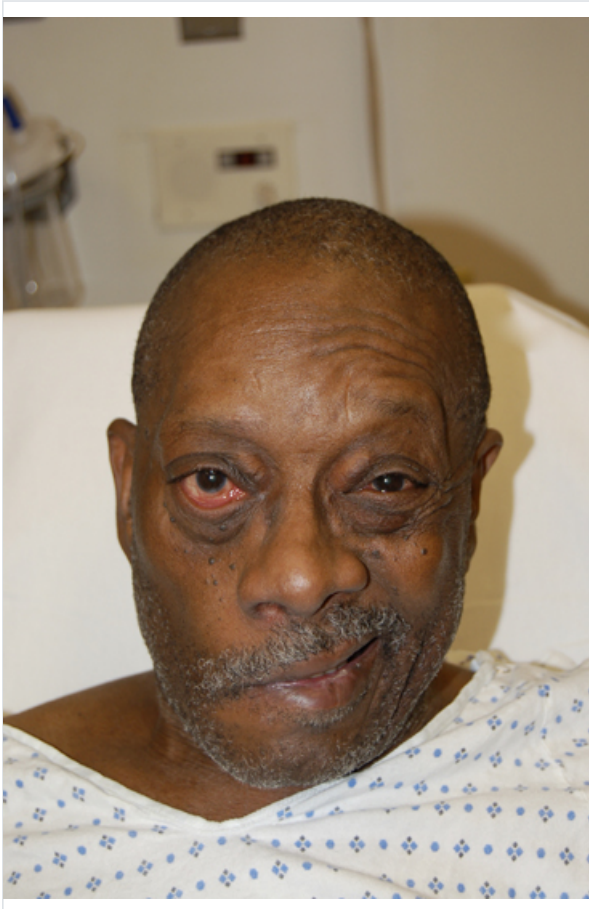

**A) Normal face, smiling and raising eyebrows. Photo courtesy Michael T. Mullen**





**B) Stroke causing isolated left lower facial weakness. There's a flattened nasolabial fold and inability to smile on the affected side with sparing of the forehead and eye closure muscles. Photo courtesy Michael T. Mullen**



**C) Bell's palsy with upper and lower facial weakness. Note the flattening of the nasoabial fold, widened palpebral fissure, and absence of forehead wrinkles on the right. Photo Edward T. Dickinson**

## Conclusion

In summary, when assessing a patient with acute facial weakness: 1) Talk to the patient; 2) Examine the muscles in the upper and lower face; and 3) Look for associated signs and symptoms. If the facial weakness is isolated to the lower face, stroke is the most likely diagnosis. If the facial weakness involves both the upper and lower face, you must look for associated signs and symptoms. Bell's palsy typically occurs in younger patients, has a slower onset of symptoms, and occurs in isolation without other complaints or objective findings on exam.

The patient described in the case is old enough to be at risk for both Bell's palsy and stroke. She awoke with symptoms so it's impossible to know how rapidly the weakness developed—it could've developed slowly over hours or been more rapid. Her facial weakness involves the upper and lower face. Because she has no other neurologic complaints and her neurologic examination is otherwise normal, her symptoms are most likely due to Bell's palsy.

## More Patient Assessment from JEMS.com

## References

1. Gilden D. Clinical practice. Bell's palsy. *N Engl J Med*. 2004;351(13):1323–1331.
2. Blumenfeld H: *Neuroanatomy through clinical cases*, 2nd edition. Sinauer Associates: Sunderland, Mass., 2010.
3. Rowland LP, Pedley TA: *Merritt's neurology*, 12th edition. Lippincott Williams & Wilkins: Philadelphia, Pa., 2010.
4. Caplan LR: *Basic pathology, anatomy, and pathophysiology of stroke*. In LR Caplan, *Caplan's stroke: A clinical approach*, 4th edition. Saunders Elsevier: Philadelphia, Pa., 2009.
5. Benatar M, Edlow J. The spectrum of cranial neuropathy in patients with Bell's palsy. *Arch Intern Med*. 2004;164(21):2383–2385.

## By

[Caitlin Loomis, MD](#) [Caitlin Loomis, MD](#)

Caitlin Loomis, MD, is a vascular neurology fellow at the University of Pennsylvania Perelman School of Medicine and Hospital of the University of Pennsylvania.

[Michael T. Mullen, MD](#) [Michael T. Mullen, MD](#)

Michael T. Mullen, MD, is assistant professor of neurology at the University of Pennsylvania Perelman School of Medicine and Hospital of the University of Pennsylvania.