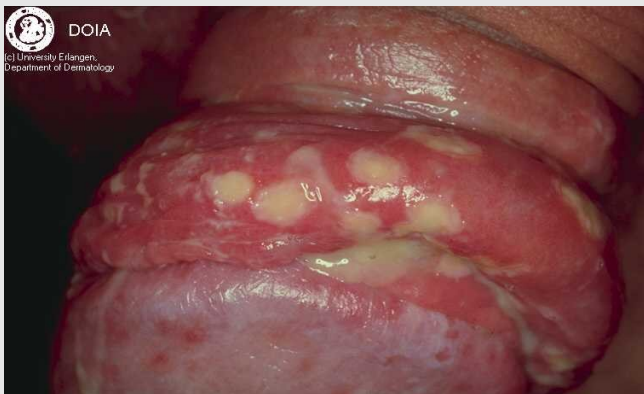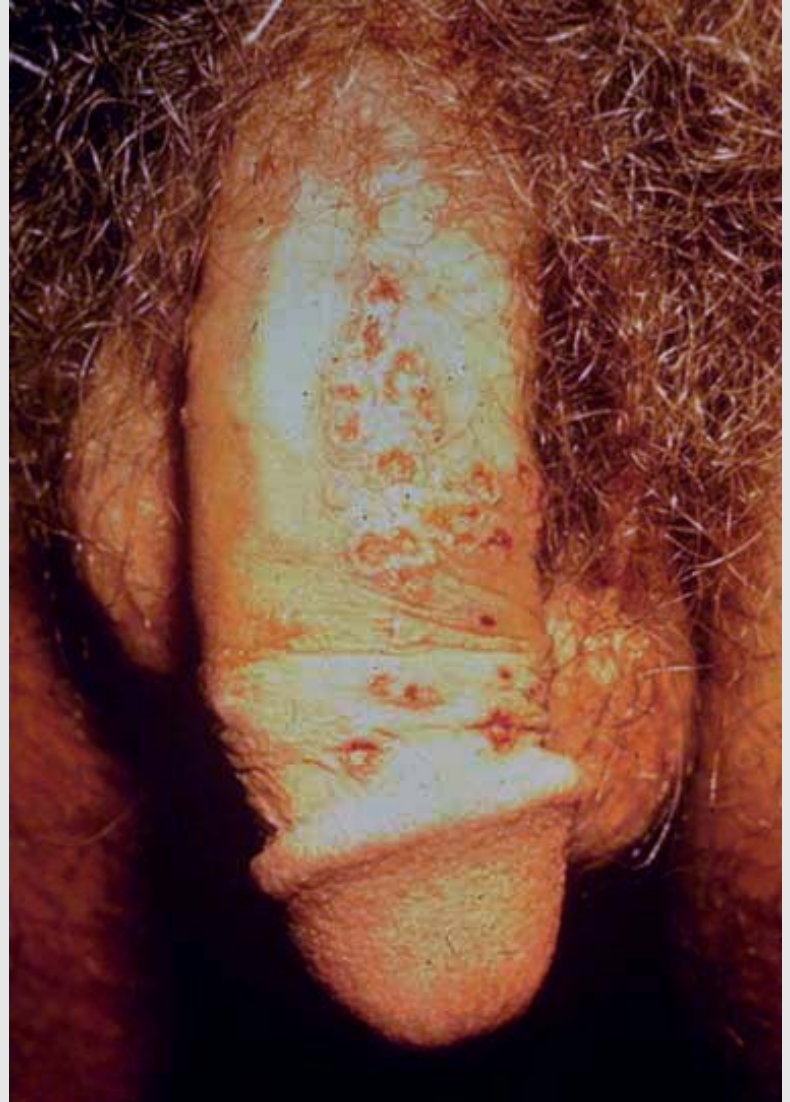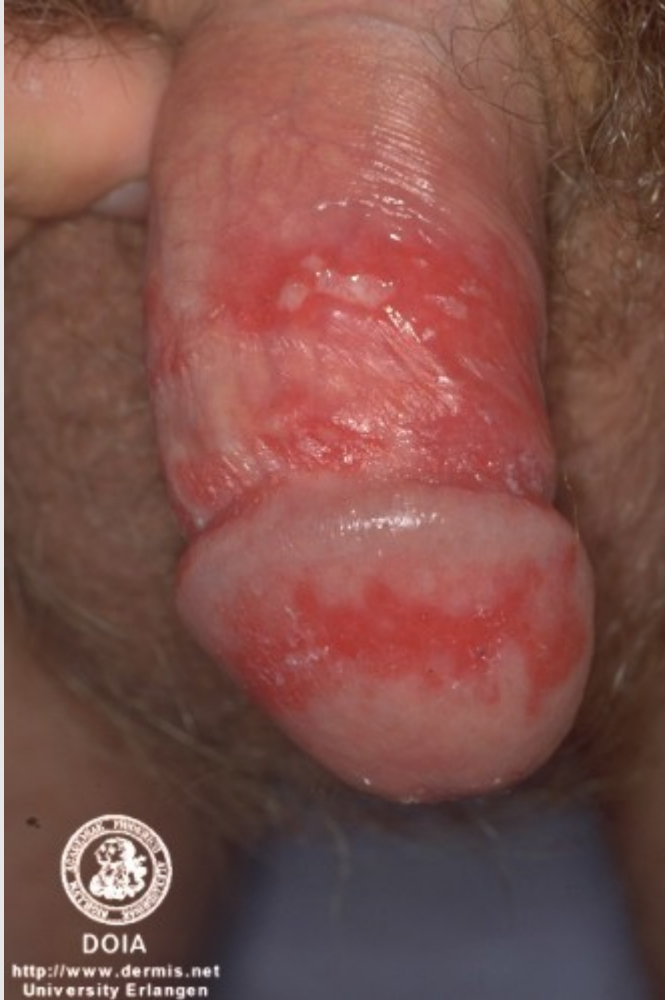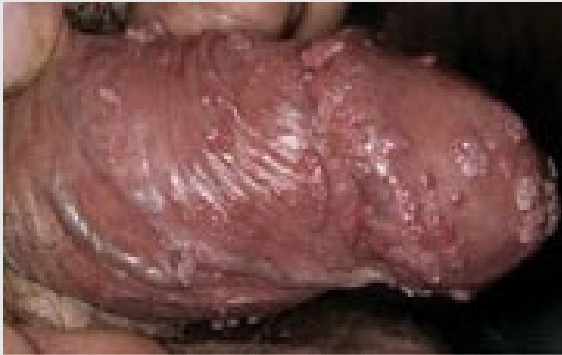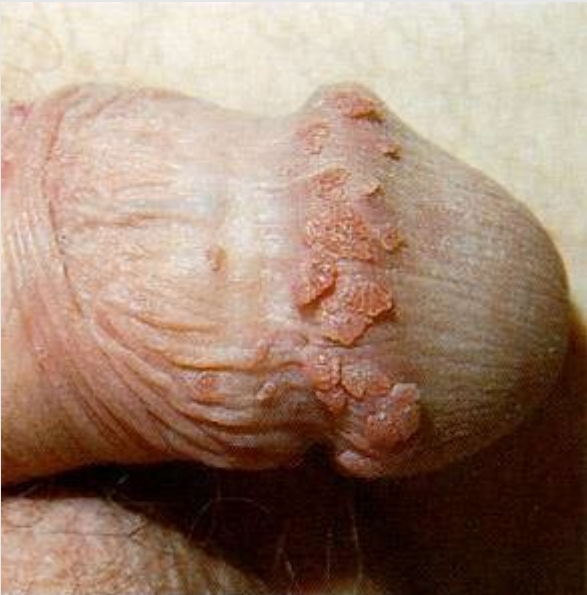


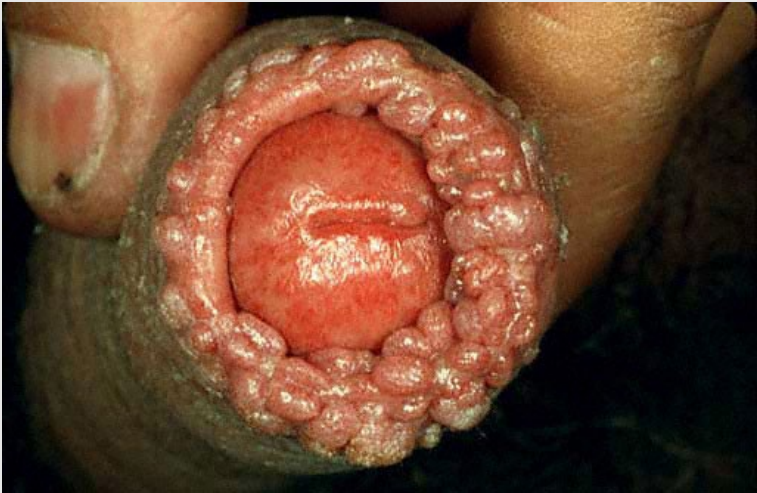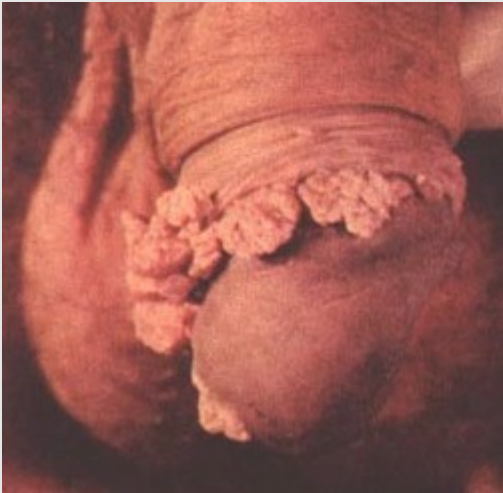Sexually Transmitted Infections

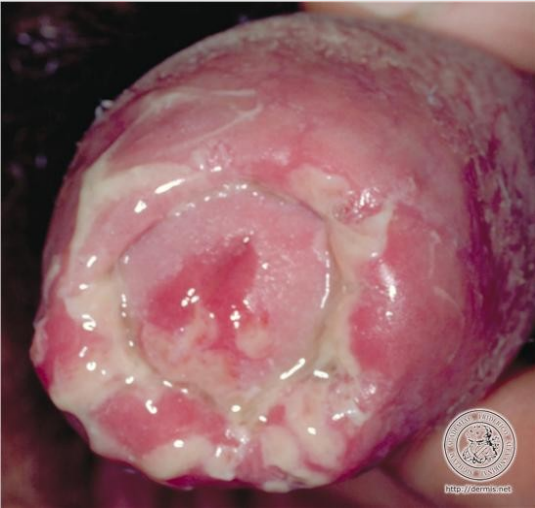HERPES



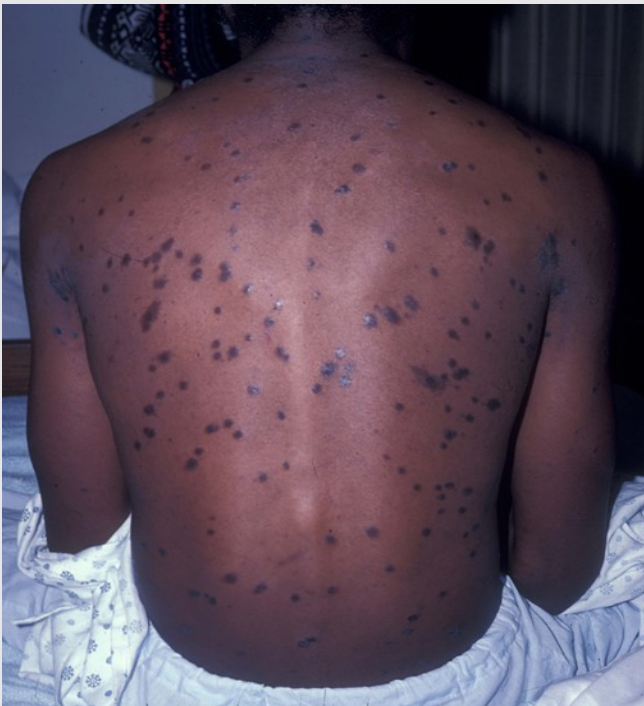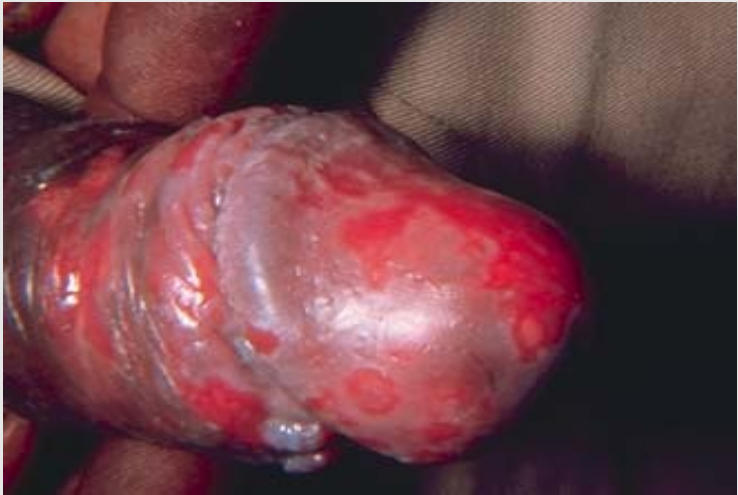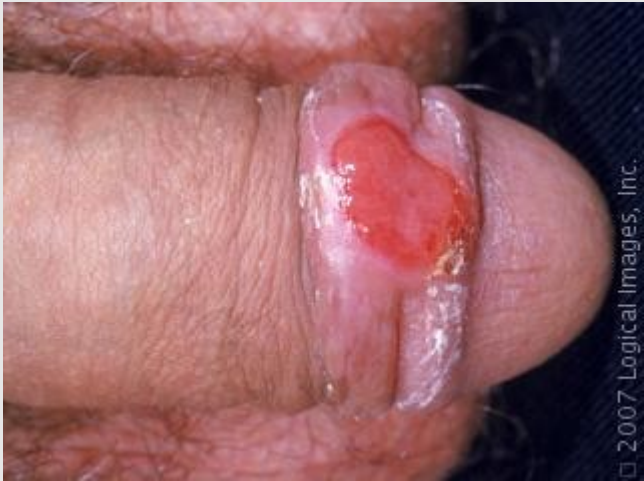GENITAL WARTS



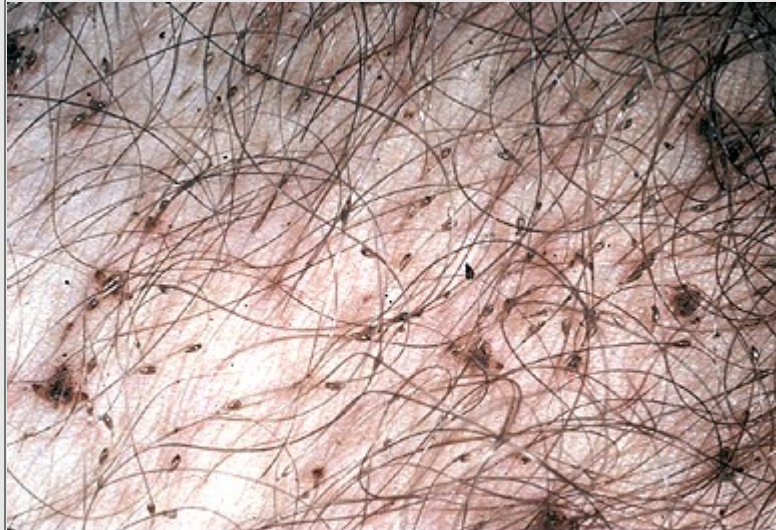GONORRHOEA



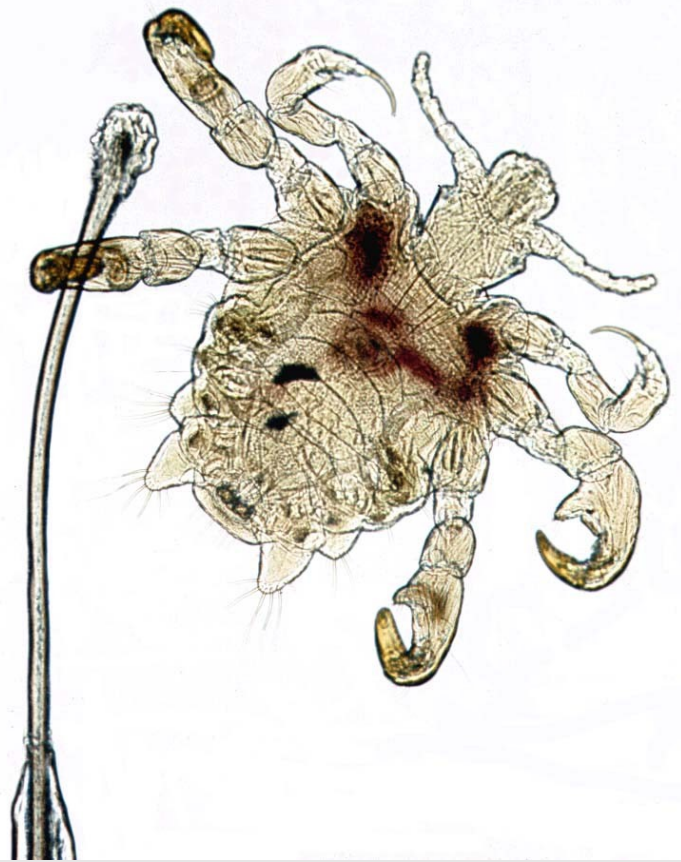SYPHILIS



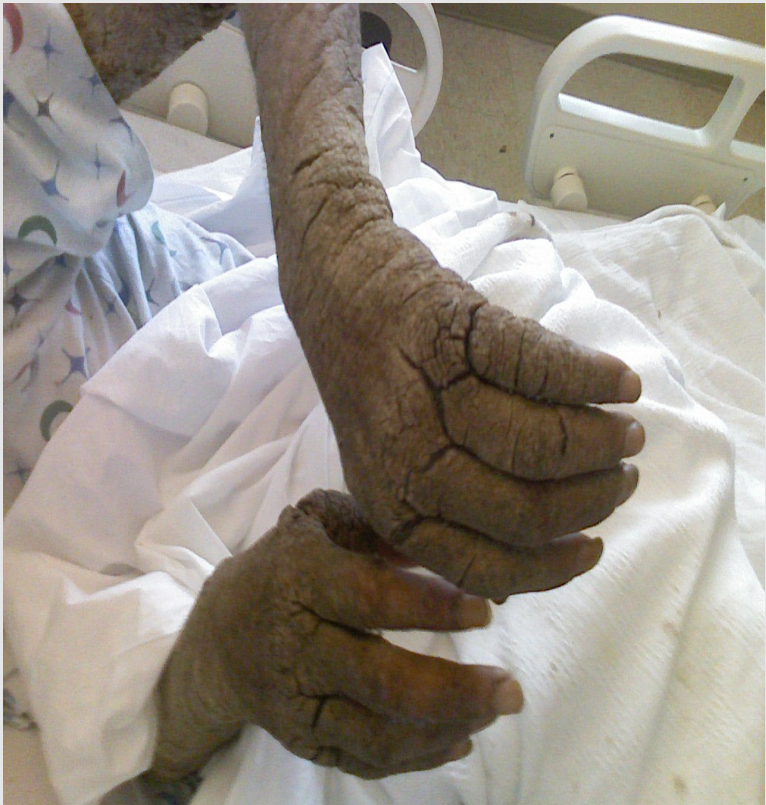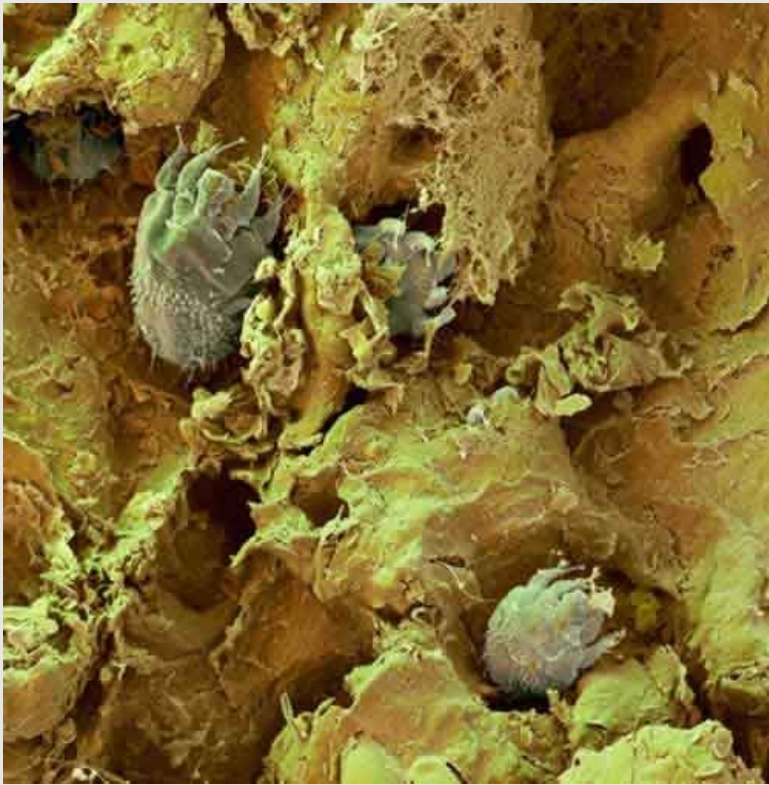
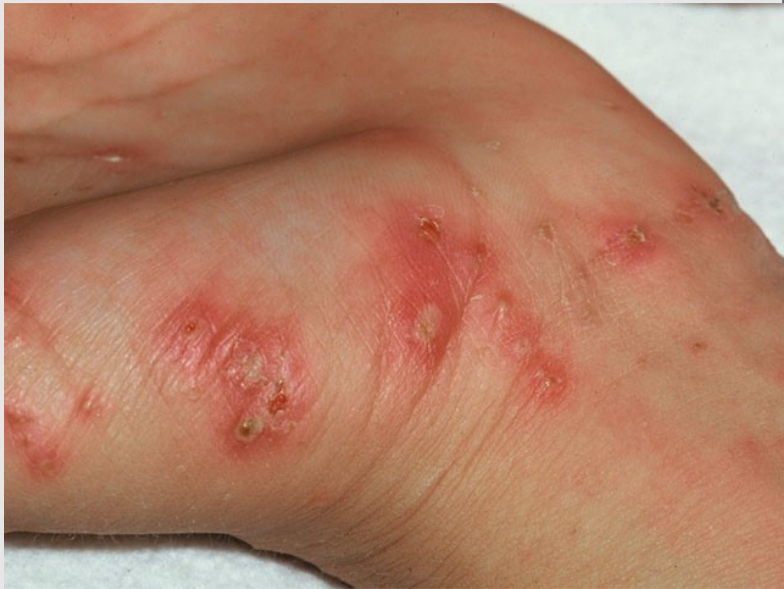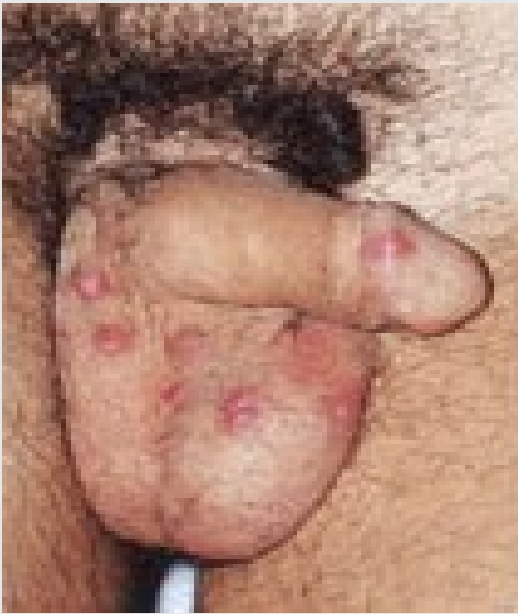PUBIC LICE/CRABS



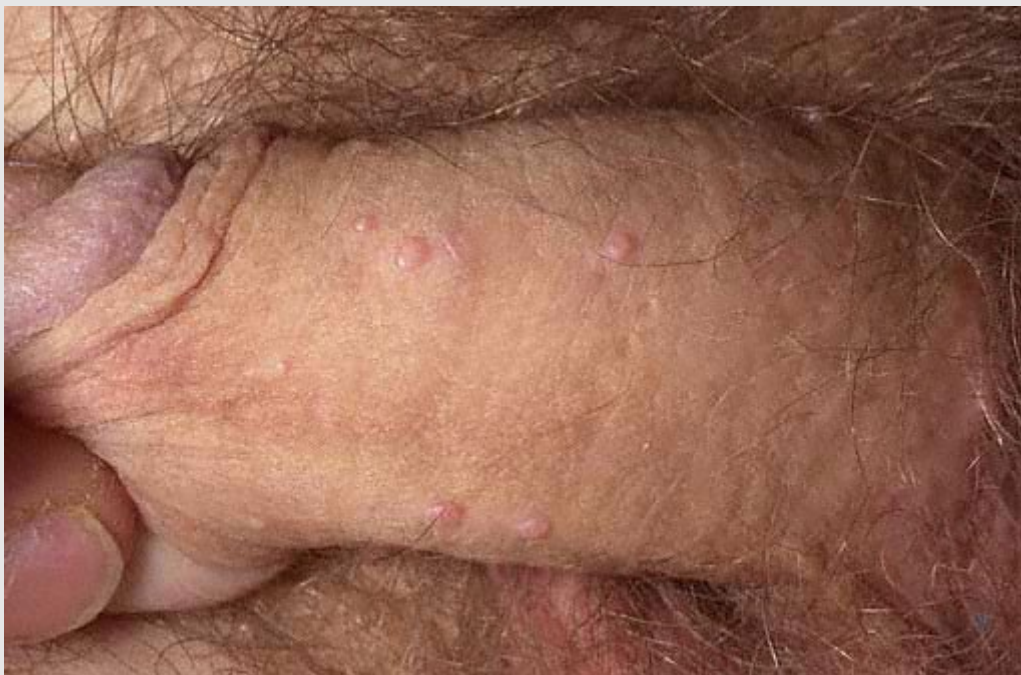Pediculosis pubis Numerous lice and nits located around the pubic hair. (Photo courtesy of John T Crissey, MD.)



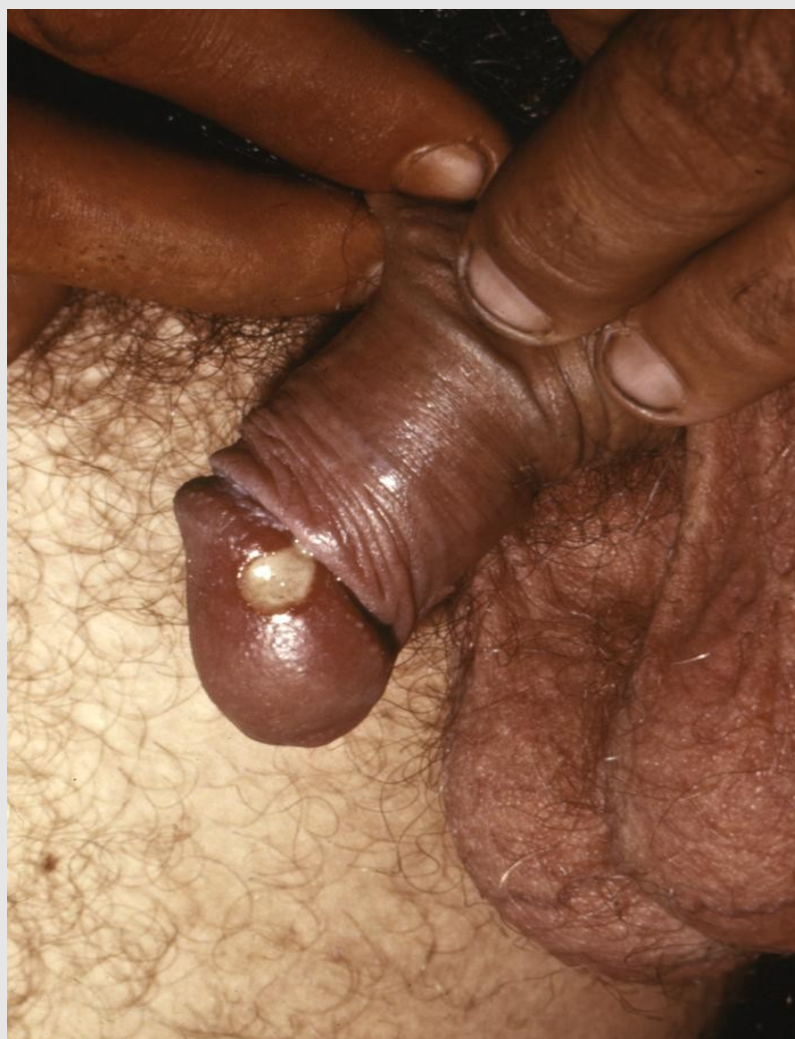SCABIES



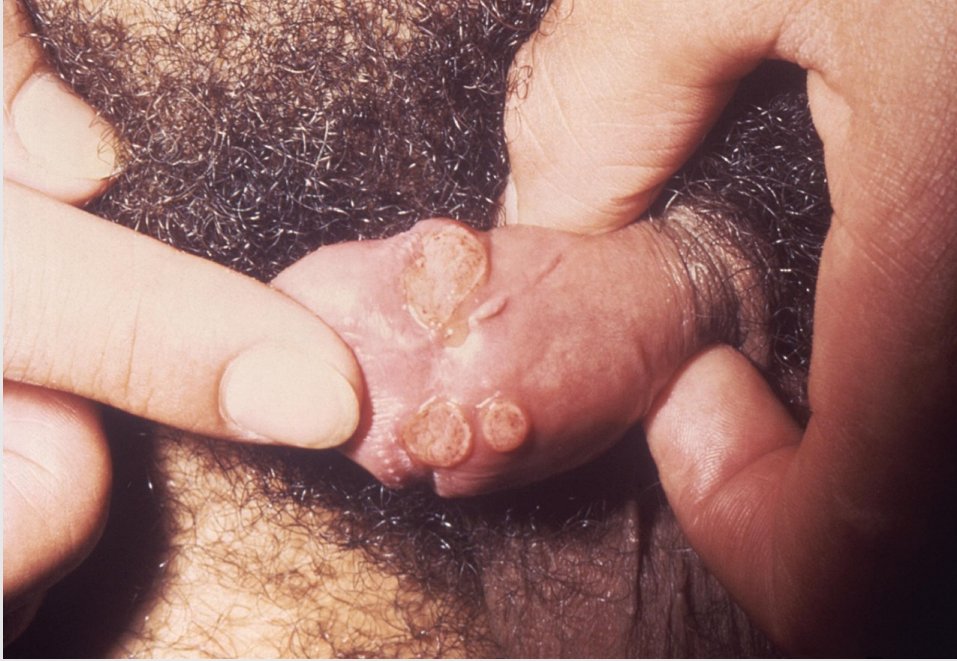MOLLOSCUM CONTAGIOSUM



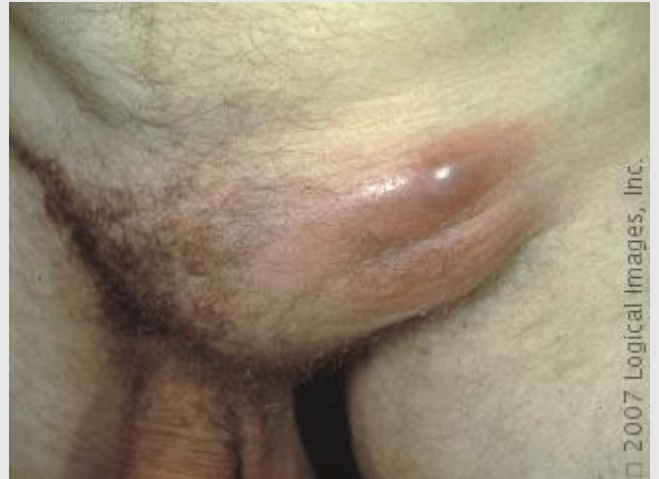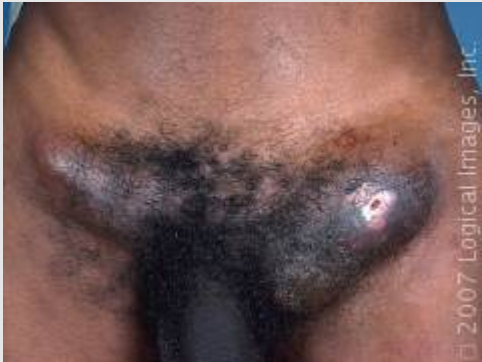CHANCROID



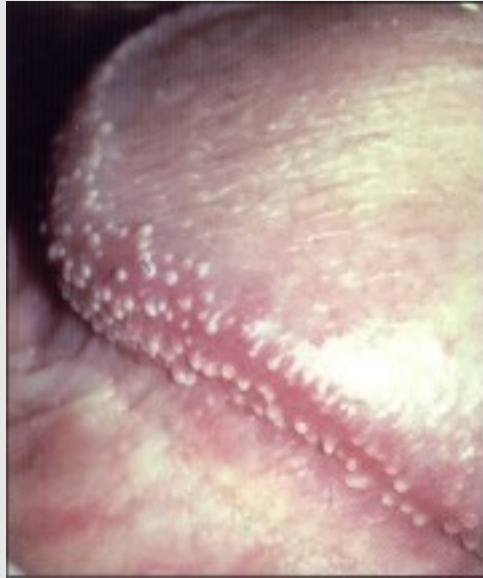DONOVANOSIS



Lymphogranuloma venereum (LGV)



Coronal Papillae/Pearly Penile Papules



Benign condition – Pearly penile papules are small dome-shaped to filiform skin-colored papules that typically are located on the sulcus or corona of the glans penis. Commonly, lesions are arranged circumferentially in one or several rows and often are assumed wrongly to be transmitted sexually. They are present in upto 48% of men and are more common in uncircumcised men.